

An Unusual Case of Severe Hypertriglyceridemia and Splenomegaly

Amit R. Rahalkar,¹ Jian Wang,¹ Sandra Sirrs,² James Dimmick,³ Daniel Holmes,⁴ Nadine Urquhart,⁴
Robert A. Hegele,^{1*} and Andre Mattman²

CASE

A 49-year-old man of Japanese and British ancestry was referred to a metabolic diseases clinic for evaluation 5 months after nontraumatic spleen rupture requiring splenectomy. Prior history included hypertension and mild frontal headaches, but no other neurological or cardiovascular symptoms. The patient did not smoke and used alcohol infrequently. His mother had coronary artery disease, and his father had mild hypertension. There was no family history of consanguinity, splenomegaly, diabetes, or developmental delay.

The ruptured spleen weighed 727 g, and splenomegaly was associated with marked sinus histiocytosis spreading apart the lymphoid component. The overwhelming majority of histiocytes were foamy (Fig. 1a), and only a few had sea-blue appearance and reacted positively with periodic acid-Schiff (PAS), PAS and diastase, and May-Giemsa stains. A lipid storage disorder was suspected, but the histiocytes did not have the cytoplasmic linearity appearance of Gaucher cells and were otherwise nonspecific. Before splenic rupture, the patient's lipoprotein profile was reported as being normal, with no past recorded triglyceride measurement exceeding 2 mmol/L.

Two-month postsplenectomy laboratory investigations revealed combined hyperlipidemia with plasma total cholesterol, HDL-cholesterol, and triglycerides of 7.9 (normal <5.2), 1.4 (normal >1.0), and 4.3 (normal <1.7) mmol/L, respectively. Liver function tests were normal aside from increased γ glutamyltransferase (88 $\mu\text{g/L}$; normal <49 $\mu\text{g/L}$). Hemoglobin and leukocyte counts were normal with mild thrombocytosis. Physical examination at 5 months revealed obesity

(body mass index 28.9 kg/m^2) and hypertension (resting blood pressure 140/100 mm Hg). Cardiovascular examination was normal. There were no xanthomata or xanthelasmata and no hepatomegaly. Left ventricular ejection fraction by echocardiogram was normal at 50%. Coronary artery computed tomographic scan revealed no obvious arterial occlusion, and brain MRI revealed nonspecific white matter changes consistent with ischemia. Carotid artery ultrasound showed no significant obstruction.

Six months postsplenectomy, the patient's plasma triglycerides were 17.2 mmol/L. He was placed on a seafood-rich, low-fat, low-sugar diet. At 8 months his plasma triglycerides had fallen to 1.5 mmol/L, while total cholesterol and HDL-cholesterol were 8.2 and 1.2 mmol/L, respectively, and apolipoprotein (apo)B and apoA-I concentrations were 1.19 and 1.35 g/L, respectively. The patient's dietary regimen was relaxed, and at 12 months triglycerides had again increased to 21.1 mmol/L. In view of findings suggesting cardiovascular disease and recurrent severe hypertriglyceridemia, aspirin and antihypertensive, and lipid-lowering therapies (atorvastatin 10 mg/day and salmon oil 3 g/day) were initiated. Genomic investigation was requested.

DISCUSSION

Primary hypertriglyceridemia is a family of relatively common disorders, some of which have a known molecular genetic basis. For instance, some cases of familial chylomicronemia result from mutations in the gene encoding lipoprotein lipase or its cofactor apoC-II. Some cases of familial combined hyperlipoproteinemia result from mutations in the upstream transcription factor 1 (*USF1*) gene encoding a transcription factor. Dysbetalipoproteinemia (type III hyperlipoproteinemia) requires 2 copies of the binding defective *APOE* E2 allele. Most cases of primary hypertriglyceridemia, however, do not have a known molecular basis. Secondary factors that worsen hypertriglyceridemia include poor diet, obesity, alcohol use, diabetes, renal disease, pregnancy, nonalcoholic fatty liver disorder, paraproteinemias, autoimmune disorders, and certain medications, such as steroids.

¹ Robarts Research Institute and Schulich School of Medicine and Dentistry, University of Western Ontario, London, Ontario, Canada; ² Adult Metabolic Disease Clinic, Department of Medicine, Vancouver General Hospital, UBC, Vancouver, British Columbia, Canada; ³ Department of Pathology and Laboratory Medicine, Children's and Women's Health Centre of British Columbia, UBC, Vancouver, British Columbia, Canada; ⁴ Department of Pathology and Laboratory Medicine, St. Paul's Hospital, UBC, Vancouver, British Columbia, Canada.

* Address correspondence to this author at: Robarts Research Institute, 406-100 Perth Drive, London, Ontario, Canada N6A 5K8. Fax: +1 519 663 3037; e-mail hegele@robarts.ca.

Previously published online at DOI: 10.1373/clinchem.2007.097139

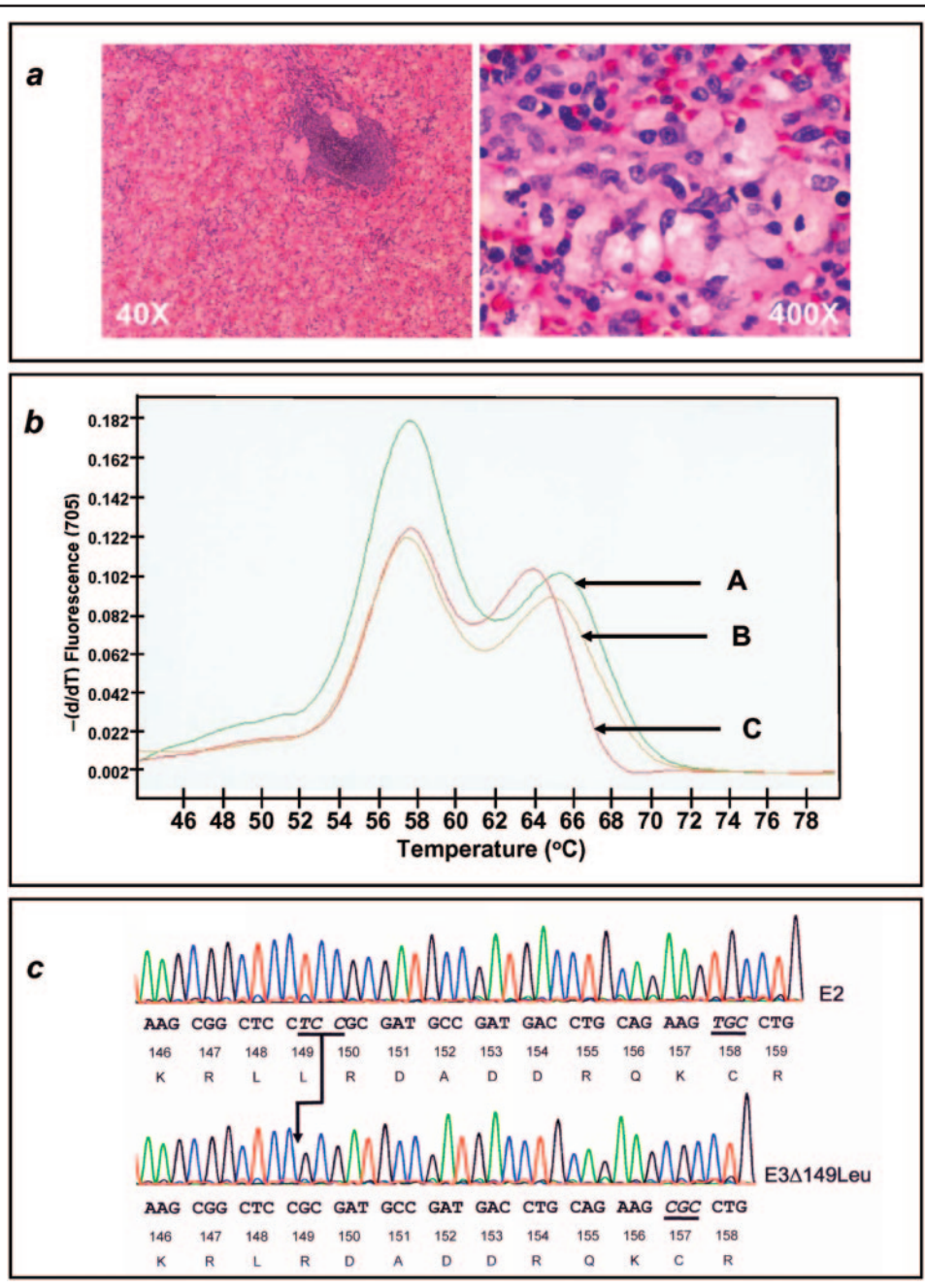


Fig. 1. Pathology and genomic studies of the index patient.

(a), Hematoxylin and eosin–stained section (40×) of spleen, showing expanded white pulp displacing Malpighian bodies. The pallor is due to the abundance of foamy histiocytes in the sinusoids, seen in inset (400X). (b), LightCycler (Roche Diagnostics) analysis of genomic DNA with curve C representing the patient’s *APOE* melting curve at codon 158, showing heterozygosity at codon 158 for 1 TGC trinucleotide (cysteine) with T_m of 56.4 °C and 1 indeterminate trinucleotide coding sequence with a melting temperature of 62.99 °C, which was outside the Cys158 acceptable range of 63.5–68.5 °C, indicating another amino acid encoded by this residue. Melting curves for normal E2/E4 (A) and E2/E3 (B) controls are shown for reference. (c), Direct sequencing of the patient’s plasmid cloned *APOE* alleles showing inframe deletion at codon 149 in the mutant allele; CGC encoding arginine at codon 157 in the bottom tracing identifies E3Δ149Leu. The TGC trinucleotide encoding cysteine at codon 158 in the top tracing identifies normal E2.

Table 1. Key biochemical, clinical and genetic features of index patient and previously reported apo E3 Δ 149Leu carriers.

Case report	(4)	(4)	(5)	(5)	(5)	Present report
Study participant	Patient 1	Patient 2	Patient 3	Brother of patient 3	Mother of patient 3	Present patient
Age, Sex	29, M	49, M	47, M	47, M	F	49, M
<i>APOE</i>						
Allele 1	E3	E3	E2	E3	E3	E2
Allele 2	E3 Δ 149Leu	E3 Δ 149Leu	E3 Δ 149Leu	E3 Δ 149Leu	E3 Δ 149Leu	E3 Δ 149Leu
Hypertension	NA ^a	NA	+	NA	NA	+
Splenomegaly	+	+	+	+	–	+
Splenectomy	+	+	+	–	–	+
Sea-blue histiocytosis						
Spleen	+	+	+	NA	NA	+
Bone marrow	NA	–	+	NA	NA	–
Hypertriglyceridemia						
Presplenectomy	–	–	+	±	+	NA
Postsplenectomy	+	+	+	NA	NA	+
Hypercholesterolemia						
Presplenectomy	–	–	+	±	NA	–
Postsplenectomy	+	+	+	NA	NA	+
Thrombocytopenia	+	+	+	+	–	–
Aminotransferase	Elevated	Elevated	Elevated	Elevated	NA	Normal
Cardiovascular disease	CAD	CAD	–	IHD	NA	Normal
Other comorbidities	–	Angina	Diabetes mellitus		Hypothyroidism, Parkinson disease	–
Treatment	Gemfibrozil, low-fat diet	Gemfibrozil, low-fat diet	NA	Gemfibrozil, atorvastatin ^b	Atorvastatin	Atorvastatin, low-fat diet, fish oil

^a NA, not available; CAD, coronary artery disease; IHD, ischemic heart disease.

^b Both medications were poorly tolerated and later discontinued.

The potential etiologies of splenomegaly vary with the patient's age. For example, splenic sequestration in sickle cell disease occurs early in life, whereas noncirrhotic portal fibrosis occurs at older ages. Mechanisms of splenomegaly include: (a) infections, which may be viral, such as Epstein-Barr virus and cytomegalovirus, bacterial, protozoal, and fungal, and in endemic areas, malaria and schistosomiasis; (b) autoimmune disorders such as juvenile rheumatoid arthritis; (c) hemolysis; (d) neoplasia, such as acute lymphoblastic leukemia, non-Hodgkin lymphoma, Hodgkin disease, and acute or chronic myeloblastic leukemia; (e) metastatic involvement, such as neuroblastoma; (f) histiocytosis; (g) obstructed splenic venous circulation due to portal vein thrombosis, hepatic cirrhosis, or congestive heart failure; (h) extrahepatic portal

venous obstruction, such as cavernous transformation; and (i) storage diseases, such as Gaucher or Niemann-Pick disease.

The differential diagnosis of nontraumatic splenomegaly with hypertriglyceridemia includes: hereditary absence of lipoprotein lipase or apoC-II, rare apoE3 mutations, deficiency of lysosomal acid lipase, or hemophagocytic lymphohistiocytosis (1–3). Work-up of these particular rare conditions includes a complete lipoprotein profile; advanced lipoprotein assays, such as *APOE* genotyping; abdominal ultrasound imaging to document liver and/or spleen enlargement; and evaluation of serum hematologic and inflammatory biomarkers. Molecular analysis of apolipoprotein E (*APOE*), apolipoprotein C-II (*APOC2*), lipoprotein lipase (*LPL*), or lipase A (lysosomal acid, cholesterol

esterase, *LIPA*) genes may be required, in addition to histopathological evaluation of the spleen.

Two previous reports have identified the existence of a very rare apoE3 isoform with a leucine deletion at codon 149, designated E3 Δ 149Leu (4, 5). Clinical features observed in patients with the E3 Δ 149Leu mutation include hypertriglyceridemia, thrombocytopenia, splenomegaly, and splenic foamy histiocyte infiltration with sea-blue histiocytosis.

The case patient underwent DNA *APOE* genotyping performed with the LightCycler (Roche Diagnostics), and the results showed that the patient was homozygous for trinucleotide TGC at codon 112 (Cys112), a finding that is consistent with apoE2 and -E3 isoforms, whereas a finding of atypical amplification at codon 158 was inconsistent with E2, E3, or E4 isoforms (Fig. 1b). *APOE* direct sequencing revealed a trinucleotide TCC deletion on 1 allele spanning codons 149 and 150, predicting an inframe leucine deletion at residue 149. To confirm the precise sequence and chromosomal phase of the mutation, plasmid vector subcloning of *APOE* exon 4 using primers F4 and F6 (5), pcDNA3+ plasmid and *E. coli* DH5 α TM (Invitrogen) was performed to sequence each of the patient's *APOE* alleles individually. The deletion was found on the E3 allele (Fig. 1c), confirming the patient's *APOE* genotype as apo E2/E3 Δ 149Leu.

Apo E mediates uptake of cholesterol-rich lipoproteins by hepatocytes. It is a ligand for LDL receptors (LDLRs) and is also a structural component of chylomicron remnants and VLDLs, enabling their removal from plasma (6). Apo E is normally incorporated into VLDL during hepatic synthesis. After secretion into plasma, VLDL is converted to LDL and the minor intermediate species, including VLDL remnants and IDLs, are catabolized via uptake through the LDLR mediated by apoE residues 136 through 150 (6, 7). ApoE is also secreted into plasma by macrophages and extrahepatic tissues, where it binds HDL, facilitating its removal from plasma (6).

A common polymorphism in the *APOE* gene affects coding sequences for amino acid residues 112 and 158, resulting in 3 protein isoforms and 6 codominant genotypes. The E3 isoform is most common (approximately 75% of all apo E alleles), and contains a cysteine at position 112 and arginine at position 158 (8). The alleles encoding the E2 and E4 isoforms each differ from the E3 allele by a single nucleotide. The E4 isoform (approximately 15% of all alleles) has arginine at position 112 and is associated with approximately 5% higher concentrations of LDL cholesterol. The E2 isoform (approximately 10% of all alleles) has cysteine at position 158 and is associated with approximately 5% lower concentrations of LDL cholesterol (8). In all populations, E3/E3 homozygosity is the most common

genotype (8). E2/E2 homozygosity occurs in approximately 1% of the population and contributes to expression of type III hyperlipoproteinemia, characterized by roughly equimolar elevations of plasma cholesterol and triglycerides and by early cardiovascular disease (9). Other rare mutations of *APOE* are also associated with dyslipidemia (7).

Nguyen et al. (4) first identified the E3 Δ 149Leu mutation in 2 unrelated probands. In both families, the mutation was associated with a dominant syndrome involving sea-blue histiocytosis and splenomegaly. Faivre et al. (5) later found the same E3 Δ 149Leu mutation in a proband presenting with clinical type III hyperlipoproteinemia, and subsequently found the mutation in several relatives. The current case shares the dyslipidemia phenotype and need for splenectomy reported for the other reported cases, but is also distinct from the other cases because of the absence of persistent transaminase elevation, thrombocytopenia, and ischemic heart disease. This case provides further evidence that links the E3 Δ 149Leu allele to dyslipidemia with splenomegaly and infiltrates of foamy histiocytosis. This syndrome may be included in the differential diagnosis of patients with postsplenectomy hypertriglyceridemia.

POINTS TO REMEMBER

- In addition to heterozygous E3 Δ 149Leu, the differential diagnosis of nontraumatic splenomegaly with hypertriglyceridemia includes: deficiency of lipoprotein lipase or its cofactor apoC-II, deficiency of lysosomal acid lipase, or hemophagocytic lymphohistiocytosis (1–3).
- The concomitant presentation of hypertriglyceridemia and splenomegaly results from a rare subset of the conditions that lead to either clinical presentation individually. Work-up of patients with this combination includes: lipoprotein profile, apoE isoform analysis, or *APOE* genotyping; complete blood count with differential and smear; and liver function tests, including serum albumin, bilirubin, aspartate aminotransferase and alanine aminotransferase, γ glutamyltransferase, and alkaline phosphatase. Imaging studies include abdominal ultrasound, computed tomographic scanning or MRI of the left upper quadrant, or radioisotopic scanning (spleen scan). Histological evaluation after splenectomy typically reveals foamy histiocytosis and characteristic sea-blue histiocytosis. Molecular analysis of *APOE* (to detect del49Leu), *APOC2*, *LPL*, or *LIPA* genes to detect loss-of-function mutations may be required.

The E3/E3 Δ 149Leu mutation negatively affects apoE function, and carriers develop signs and symptoms of a lipid storage disease. The preferential association of the E3 Δ 149Leu mutation with splenic foam-cell formation remains to be explained. The spleen is a major triglyceride reservoir in E3 Δ 149Leu carriers, because splenectomy is followed by severe hypertriglyceridemia. Macrophages can secrete apoE into plasma and receive circulating apoE-containing lipoproteins (6), perhaps explaining why the macrophage-rich spleen behaves like a lipid sponge.

A comparison with earlier case reports suggests that the dyslipidemia in E3 Δ 149Leu carriers shows remarkable clinical heterogeneity (Table 1). We speculate that the clinical and pathological sequelae attributable to the E3 Δ 149Leu mutation depend on a combination of genetic and environmental factors. From this case study and others, we may conclude that apo E3 Δ 149Leu causes a lipid-storage disease characterized by splenomegaly, splenic infiltration with foamy and sea-blue histiocytes, and hypertriglyceridemia that may be unmasked following splenectomy. The disorder seems responsive to diet, lifestyle, and pharmacologic intervention.

Grant/funding Support: Supported by the Jacob J. Wolfe Distinguished Medical Research Chair, the Edith Schulich Vinet Canada Research Chair (Tier I) in Human Genetics, operating grants from the Canadian Institutes for Health Research (MOP-13430, MT-8014), the Heart and Stroke Foundation of Ontario

(NA-6059, T-5603, PRG-5967, and the Irwin Bernick Summer Student Fellowship through the University of Western Ontario) and by Genome Canada through the Ontario Genomics Institute.

Financial Disclosures: None declared.

References

1. Janka GE. Hemophagocytic syndromes. *Blood Rev* 2007;21:245–53.
2. Tylki-Szymanska A, Rujner J, Lugowska A, Sawnor-Korszynska D, Wozniwicz B, Czarnowska E. Clinical, biochemical and histological analysis of seven patients with cholesteryl ester storage disease. *Acta Paediatr Jpn* 1997;39:643–6.
3. Saku K, Cedres C, McDonald B, Hynd BA, Liu BW, Srivastava LS, Kashyap ML. C-II anapolipoproteinemia and severe hypertriglyceridemia: report of a rare case with absence of C-II apolipoprotein isoforms and review of the literature. *Am J Med* 1984;77:457–62.
4. Nguyen TT, Kruckeberg KE, O'Brien JF, Ji ZS, Kames PS, Crotty TB, et al. Familial splenomegaly: macrophage hypercatabolism of lipoproteins associated with apolipoprotein E mutation [apolipoprotein E (Δ 149 Leu)]. *J Clin Endocrinol Metab* 2000;85:4354–8.
5. Faivre L, Saugier-Verber P, Pais de Barros JP, Verges B, Couret B, Lorcerie B, et al. Variable expressivity of the clinical and biochemical phenotype associated with the apolipoprotein E p.Leu149del mutation. *Eur J Hum Genet* 2005;13:1186–91.
6. Lucic D, Huang ZH, Gu de S, Altenburg MK, Maeda N, Mazzone T. Regulation of macrophage apoE secretion and sterol efflux by the LDL receptor. *J Lipid Res* 2007;48:366–72.
7. Walden CC, Hegele RA. Apolipoprotein E in hyperlipidemia. *Ann Intern Med* 1994;120:1026–36.
8. Eichner JE, Dunn ST, Perveen G, Thompson DM, Stewart KE, Stroehla BC. Apolipoprotein E polymorphism and cardiovascular disease: a HuGE review. *Am J Epidemiol* 2002;155:487–95.
9. Mahley RW, Rall SC. Type III hyperlipoproteinemia (dysbetalipoproteinemia): the role of apolipoprotein E in normal and abnormal lipoprotein metabolism. In: Scriver CR, Beaudet AL, Sly WS, Valle D, editors. *The metabolic and molecular bases of inherited disease*. 8th ed. New York: McGraw-Hill; 2001. p 2835–62.

Commentary

Alan T. Remaley

Although apolipoprotein (apo)A-I and apoB are measured by many laboratories as an adjunct to HDL and LDL concentrations, respectively, lipoproteins contain numerous other proteins, some of which have a profound effect on lipoprotein metabolism. ApoE, for example, resides on both antiatherogenic HDL particles and on proatherogenic apoB-containing lipoproteins, thus confounding the usefulness of apoE as a cardiovascular risk marker in unfractionated samples. Nevertheless, apoE has many different roles in lipoprotein metabolism, some of which may account for the mac-

rophage lipid accumulation observed in this interesting case. The best understood function of apoE is that it can serve as a ligand for the cellular uptake of apoB-containing proteins, as well as perhaps HDL, by various receptors. In the absence of a normal form of apoE, there is decreased hepatic clearance of lipoproteins, which leads to their increased oxidation and uptake by macrophage scavenger receptors. ApoE can also help prevent lipid accumulation in cells, particularly in macrophages, which synthesize apoE, by promoting the efflux of excess intracellular cholesterol by the ABCA1 transporter and by other cholesterol efflux mechanisms.

Recently, a new role for apoE has been described, which may also be relevant to the macrophage lipid accumulation observed in this case. The presence of apoE on lipoproteins also facilitates the lysosomal pro-

National Institutes of Health, Bethesda, MD.
Address correspondence to the author at: National Institutes of Health, Bldg. 10, Rm. 2C-433, 10 Center Dr, MSC 1508, Bethesda, MD, 20892-1508. Fax 301-402-1885; e-mail aremaley@nih.gov.
Previously published online at DOI: 10.1373/clinchem.2007.101881

cessing of endocytosed lipoproteins (1). In the absence of apoE or possibly, as in this case, in the presence of an abnormal form of apoE, the endocytosed lipoproteins interfere with the delivery of the various hydrolytic enzymes to the lysosome, by perhaps altering the production and/or trafficking of the mannose-6-phosphate receptor, which normally shepherds these enzymes to the lysosome. This interference results in a defect in the intracellular lipolysis of lipoproteins and the accumulation of cholesteryl esters in lysosomes. In addition, cathepsin B, normally a lysosomal proteolytic enzyme, is instead secreted into the extracellular space, where it may contribute to the formation of unstable plaques. Currently, the only apoE-based test routinely performed in clinical laboratories is a genotype type test

Commentary

Robert Shamburek

Clinical laboratories typically focus on apolipoprotein (apo)E typing of polymorphisms (E2, E3, E4) and less on apoE concentrations, because increased apoE is found in hypertriglyceridemia but correlates less with coronary heart disease. The role of apoE and the importance of splenic macrophages in lipoprotein metabolism are highlighted by this case.

Type III hyperlipoproteinemia (HLP) is inherited either in a recessive or dominant mode. Recessively inherited type III HLP requires homozygosity of apoE2, but E2/2 alleles alone are not enough for development of the lipid and clinical phenotype, because <10% of apoE2/2 homozygotes produce the phenotype. A “second hit” consisting of genetic, hormonal, and environmental factors including obesity, estrogen status, or diabetes are required to develop the phenotype. In contrast, apoE3 Δ 149Leu is a rare dominantly inherited form of type III HLP that is attributable to a single defective apoE allele. This phenotype lacks the “classical” tuberous and palmar xanthoma seen in recessive type III HLP, and the lipid profile in apoE3 Δ 149Leu depends more on an intact spleen than a second hit.

for apoE isoforms, for assessing the risk of Alzheimer disease. Given the multifaceted role of apoE in lipoprotein metabolism, the measurement of apoE on specific lipoprotein fractions may be a fruitful area for future research on cardiovascular risk markers.

Grant/funding Support: None declared.

Financial Disclosures: None declared.

Reference

1. Wu D, Sharan C, Yang H, Goodwin JS, Zhou L, Grabowski GA, Du H, Guo Z. Apolipoprotein E-deficient lipoproteins induce foam cell formation by down-regulation of lysosomal hydrolases in macrophages. *J Lipid Res* 2007;48:2571–8.

The spleen plays an important and protective role in clearing the plasma of triglyceride-remnant lipoproteins. Development of hepatosteatosis and splenomegaly appears to occur as a result of hypercatabolism of mutant apoE-containing triglyceride-remnant lipoproteins by splenic macrophages. Enhanced macrophage uptake contributes to the relatively normal plasma lipid concentrations with an intact spleen.

Splenectomy unmasks the remnant lipoprotein defect and leads to the development of hypertriglyceridemia. Then, diet and secondary factors modulate the overproduction of lipoproteins (β -VLDL) concomitantly with the defective removal.

The spleen plays an important role in the abnormal clearance that occurs in other lipid disorders such as Tangier disease. The clinical picture can worsen after splenectomy. Atherosclerosis is accelerated after splenectomy owing to the decreased clearance of remnant lipoproteins, but may take 5–10 years to be clinically apparent. Splenic macrophages may be protective against the development of coronary heart disease.

Grant/funding Support: None declared.

Financial Disclosures: None declared.

Reference

1. Schaefer EJ, Triche TJ, Zech LA, Stein LA, Kemeny MM, Brennan MF, Brewer Jr HB. Massive omental reticuloendothelial cell lipid uptake in Tangier disease after splenectomy. *Am J Med* 1983;75:521–6.

National Institutes of Health, Bethesda, MD.

Address correspondence to the author at: Bldg 10 7N115, 10 Center Drive, National Institutes of Health, Bethesda, MD, 20892-1666. Fax: 301-402-0190; e-mail bobs@nhlbi.nih.gov.

Previously published online at DOI: 10.1373/clinchem.2007.101899